

# Management of antithrombotic therapy in patients undergoing transcatheter aortic valve implantation: a consensus document of the ESC Working Group on Thrombosis and the European Association of Percutaneous Cardiovascular Interventions (EAPCI), in collaboration with the ESC Council on Valvular Heart Disease

Jurrien ten Berg <sup>1,2\*</sup>, Dirk Sibbing<sup>3,4,5</sup>, Bianca Rocca <sup>6</sup>, Eric Van Belle<sup>7</sup>, Bernard Chevalier<sup>8</sup>, Jean-Philippe Collet <sup>9</sup>, Dariusz Dudek<sup>10,11</sup>, Martine Gilard<sup>12</sup>, Diana A. Gorog <sup>13,14</sup>, Julia Grapsa <sup>15</sup>, Erik Lerkevang Grove <sup>16</sup>, Patrizio Lancellotti<sup>17,18</sup>, Anna Sonia Petronio<sup>19</sup>, Andrea Rubboli<sup>20</sup>, Lucia Torracca<sup>21</sup>, Gemma Vilahur<sup>22</sup>, Adam Witkowski<sup>23</sup>, and Julinda Mehilli<sup>4,5,24</sup>

<sup>1</sup>Department of Cardiology and Center for Platelet Function Research, St Antonius Hospital, Nieuwegein, the Netherlands; <sup>2</sup>The Cardiovascular Research Institute Maastricht (CARIM), Maastricht, the Netherlands; <sup>3</sup>Privatklinik Lauterbacher Mühle am Ostersee, Seeshaupt, Germany; <sup>4</sup>Department of Cardiology, Ludwig-Maximilians-Universität München (LMU Munich), Munich, Germany; <sup>5</sup>DZHK (German Centre for Cardiovascular Research), partner site Munich Heart Alliance, Munich, Germany; <sup>6</sup>Institute of Pharmacology, Catholic University School of Medicine, Rome, Italy; <sup>7</sup>Department of Interventional Cardiology for Coronary, Valves and Structural Heart Diseases, CHU Lille, Institut Coeur Poumon, Cardiology, INSERM U1011, Institut Pasteur de Lille, Lille, France; <sup>8</sup>Ramsay Générale de Santé, ICPS, Hôpital Jacques Cartier, Massy, France; <sup>9</sup>ACTION Study Group, Institut De Cardiologie, Hôpital Pitié-Salpêtrière (APHP), Sorbonne Université, Paris, France; <sup>10</sup>Institute of Cardiology, Jagiellonian University Medical College, Krakow, Poland; <sup>11</sup>Maria Cecilia Hospital, GVM Care&Research, Cotignola (RA), Italy; <sup>12</sup>Department of Cardiology, La Cavale Blanche University Hospital Center, Optimization of Physiological Regulations, Science and Technical Training and Research Unit, University of Western Brittany, Brest, France; <sup>13</sup>National Heart & Lung Institute, Imperial College, London, UK; <sup>14</sup>Postgraduate Medical School, University of Hertfordshire, Hertfordshire, UK; <sup>15</sup>Department of Cardiology, Guys and St Thomas NHS Hospitals, London, UK; <sup>16</sup>Department of Cardiology, Aarhus University Hospital, Aarhus, Denmark; <sup>17</sup>University of Liège Hospital, GIGA Cardiovascular Sciences, Department of Cardiology, CHU Sart Tilman, Liège, Belgium; <sup>18</sup>Gruppo Villa Maria Care and Research, Maria Cecilia Hospital, Cotignola, and Anthea Hospital, Bari, Italy; <sup>19</sup>Department of Cardiology, University of Pisa, Pisa, Italy; <sup>20</sup>Department of Cardiovascular Diseases-AUSL Romagna, Division of Cardiology, Ospedale S. Maria delle Croci, Ravenna, Italy; <sup>21</sup>Department of Cardiac Surgery, Humanitas University Hospital Rozzano-Milano, Italy; <sup>22</sup>Cardiovascular Program-ICCC, IR-Hospital de la Santa Creu i Sant Pau, CiberCV, Autonomous University of Barcelona, Spain; <sup>23</sup>Department of Interventional Cardiology and Angiology, National Institute of Cardiology, Warsaw, Poland; and <sup>24</sup>Department of Cardiology, Medizinische Klinik I, Landshut-Achdorf Hospital, Landshut, Germany

Received 9 October 2020; revised 15 December 2020; editorial decision 8 March 2021; accepted 17 March 2021; online publish-ahead-of-print 5 April 2021

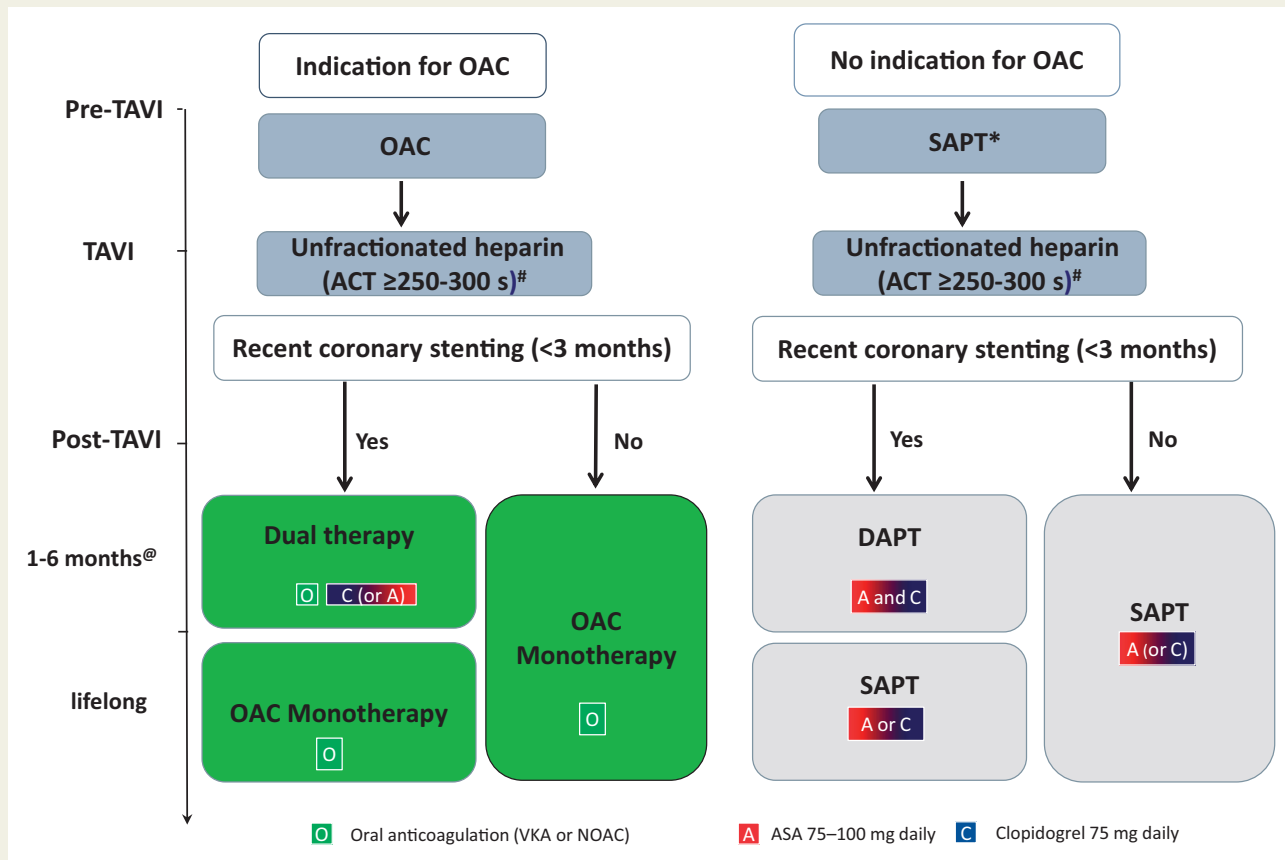
Transcatheter aortic valve implantation (TAVI) is effective in older patients with symptomatic severe aortic stenosis, while the indication has recently broadened to younger patients at lower risk. Although thromboembolic and bleeding complications after TAVI have decreased over time, such adverse events are still common. The recommendations of the latest 2017 ESC/EACTS Guidelines for the management of valvular heart disease on antithrombotic therapy in patients undergoing TAVI are mostly based on expert opinion. Based on

\* Corresponding author. Tel: 06-51167252, Email: [jurtenberg@gmail.com](mailto:jurtenberg@gmail.com)

Published on behalf of the European Society of Cardiology. All rights reserved. © The Author(s) 2021. For permissions, please email: [journals.permissions@oup.com](mailto:journals.permissions@oup.com).

recent studies and randomized controlled trials, this viewpoint document provides updated therapeutic insights in antithrombotic treatment during and after TAVI.

## Graphical Abstract



Antithrombotic treatment during and after transcatheter aortic valve implantation. The figure summarizes the consensus for treating patients who are candidate for transcatheter aortic valve implantation, according to the presence or absence of oral anticoagulation indications and to recent coronary stenting. ACT, activated clotting time; ASA, aspirin; DAPT, dual antiplatelet therapy; HIT heparin-induced thrombocytopenia; NOAC, non-vitamin-K antagonist oral anticoagulant; OAC, oral anticoagulation; SAPT, single antiplatelet therapy; TAVI, transcatheter aortic valve implantation; VKA, vitamin K antagonist. \*Low-dose aspirin or clopidogrel. <sup>#</sup>Bivalirudin if heparin-induced thrombocytopenia. <sup>@</sup>Duration according to bleeding risk.

## Keywords

Transcatheter aortic valve implantation • Antithrombotic treatment

## Introduction

Transcatheter aortic valve implantation (TAVI) is effective in older patients with symptomatic severe aortic stenosis, while the indication has recently broadened to lower risk and younger patients.<sup>1,2</sup> Thromboembolic and bleeding complications are frequent, thus an optimal antithrombotic regimen peri- and post-TAVI is of utmost importance.

The 2017 ESC/EACTS guidelines recommend either dual antiplatelet therapy (DAPT, low-dose aspirin plus clopidogrel) for 3–6 months post-TAVI, followed by life-long single antiplatelet therapy (IIa), or oral anticoagulation (OAC) for patients with other indications for OAC (Ia).<sup>1</sup> The 2020 ACC/AHA guidelines recommend

life-long low-dose aspirin post-TAVI (IIa), while aspirin plus clopidogrel or vitamin K anticoagulation (VKAs) for 3–6 months are options in patients with low bleeding risk (IIb).<sup>2</sup>

Based on recent studies and randomized controlled trials (RCTs), this viewpoint document provides updated therapeutic insights into antithrombotic treatment peri- and post-TAVI.

## Thromboembolic and bleeding complications

Stroke is prevalent, especially peri- and early post-TAVI (<1–8% in the 1st year)<sup>3–5</sup> and is attributable to dislodgment of thrombus, valve

tissue, and foreign material. Although embolic protection devices reduce peri-TAVI silent brain infarct, they have not improved outcome. Later-occurring stroke is thromboembolic, originating from the TAVI bioprosthesis or due to atrial fibrillation (AF). Also, TAVI valve thrombosis occurs, which is seldom symptomatic (1–3%).<sup>3,5</sup> Despite frequent concomitant coronary artery disease, peri-TAVI myocardial infarction (MI) is rare (1–3%).<sup>3–5</sup> Overall thromboembolic incidences are depicted in [Supplementary material online, Table S1](#).

Also, major life-threatening and disabling bleeding frequently occurs in 3–11% within the 1st year.<sup>3–5</sup> Of these, 50% is procedure-related despite improvements in access-site assessment by computed tomography (CT), ultrasound-guided puncture, smaller bore catheters, and low-profile suture-closure devices.<sup>5</sup> The older age of TAVI patients, their comorbidities, frequent presence of acquired von Willebrand factor defect and moderate thrombocytopenia post-TAVI, all increase bleeding risk and should be considered when choosing optimal antithrombotic therapy. Furthermore, bleeding risk assessment pre- and periodically post-TAVI is mandatory.

## Antithrombotic therapy peri-transcatheter aortic valve implantation

Low-dose aspirin is the treatment of choice, usually started pre-TAVI, in patients without OAC indication. Moreover, the BRAVO-3 trial showed no additional reduction of thromboembolic events peri-TAVI in patients on maintenance clopidogrel or loaded pre-TAVI.<sup>6</sup> In patients on OAC, the effect of OAC on peri-TAVI thromboembolic events is unknown. However, continuing VKA or non-vitamin K antagonist oral anticoagulant (NOAC) during TAVI seems safe, as an observational study did not show increased bleeding, transfusion, or vascular complications as compared with (N)OAC interruption.<sup>7</sup> When (N)OAC is continued during TAVI, peri-procedural aspirin is usually not needed.

During TAVI, unfractionated heparin (UFH) is routinely used [reference activated clotting time [ACT] 250–300 s] to reduce catheter thrombosis and thromboembolism. Bivalirudin is an alternative in patients with contraindications to UFH. To prevent vascular access-site complications and bleedings, protamine sulphate may be used before closure to reverse anticoagulation.

## Antithrombotic treatment post-transcatheter aortic valve implantation in patients without oral anticoagulant indication

Observational studies and a small RCT reported no difference in thromboembolic events between aspirin plus clopidogrel and aspirin alone, but DAPT increased major bleeding.<sup>8</sup> The POPular TAVI RCT (cohort A) confirmed that aspirin alone reduced bleeding compared with aspirin plus clopidogrel. Bleeding occurred in 50 patients (15.1%) receiving aspirin alone and in 89 (26.6%) receiving aspirin plus clopidogrel [risk ratio (RR) 0.57; 95% confidence interval (CI)

0.42–0.77;  $P=0.001$ ], while the composite of cardiovascular death, stroke, or MI for aspirin alone was non-inferior to aspirin plus clopidogrel (9.7% and 9.9%,  $P=0.004$  for non-inferiority).<sup>5</sup> Based on this RCT, we consider low-dose aspirin as preferred over aspirin plus clopidogrel post-TAVI in patients without OAC indication.

The recent GALILEO trial randomized patients without OAC indication to low-dose rivaroxaban (10 mg) plus aspirin for 3 months, followed by rivaroxaban alone vs. aspirin plus clopidogrel for 3 months, followed by aspirin alone. The trial was terminated early for a significant 69% relative increase in all-cause mortality, 50% increase in Valve Academic Research Consortium (VARC)-2 major, life-threatening or disabling bleeding, and 35% increase in the composite of death and thromboembolic events.<sup>3</sup> Thus, current evidence does not support rivaroxaban plus aspirin after TAVI in patients without an OAC indication.

## Antithrombotic treatment post-transcatheter aortic valve implantation in patients with oral anticoagulant indication

Almost all patients with AF undergoing TAVI (prevalence ~40%) have an indication for OAC based on the CHA<sub>2</sub>DS<sub>2</sub>-VASc score. Whether TAVI patients are best treated with VKA or NOAC is unknown. Current AF guidelines recommend NOACs over VKA in NOAC-eligible patients (class Ia, ).<sup>9</sup> Observational data show inconsistent results regarding the thromboembolic risk associated with NOACs post-TAVI. A Danish registry showed similar risk of thromboembolism, bleeding, or all-cause mortality post-TAVI among NOAC and VKA.<sup>10</sup> A German registry demonstrated higher all-cause mortality, MI, and cerebrovascular events at 1 year with NOAC vs. VKA.<sup>11</sup> Therefore, evidence supporting NOAC over VKA after TAVI in AF patients is currently lacking.

In an observational study in AF patients, VKA alone reduced major or life-threatening bleeding in comparison to VKA and aspirin with comparable ischaemic events.<sup>12</sup> The POPular TAVI (cohort B) randomized AF patients undergoing TAVI to (N)OAC alone or to (N)OAC plus clopidogrel for 3 months. Bleeding was significantly lower with (N)OAC alone vs. (N)OAC plus clopidogrel (21.7% vs. 34.6%; RR 0.63, 95% CI 0.43–0.90,  $P=0.01$ ), while the composite of cardiovascular death, stroke, or MI was non-inferior (13.4% and 17.3%, respectively; 95% CI for non-inferiority, -11.9 to 4.0).<sup>4</sup> Based on this RCT, we consider OAC alone as preferred over OAC plus clopidogrel after TAVI in patients with OAC indication.

Finally, left atrial appendage closure may be considered in patients with clear contraindication to OAC.

## Transcatheter aortic valve implantation patients undergoing percutaneous coronary intervention

Percutaneous coronary intervention (PCI) is frequently (~20%) performed shortly before, during, or after TAVI. According to the ESC

guidelines, DAPT is recommended after stenting, for 6 months in chronic coronary syndrome (CCS) and 12 months in acute coronary syndrome (ACS). In patients at high bleeding risk, DAPT duration could be shortened to 1–3 months for CCS and to 3–6 months for ACS.<sup>13</sup> Therefore, in most TAVI patients, we consider shorter DAPT duration preferable, due to underlying high bleeding risk. In TAVI patients with an indication for OAC, the optimal antithrombotic regimen post-stenting is complex. Current guidelines recommend the combination of NOAC plus clopidogrel with a very short period of aspirin (triple therapy, duration varying from only during PCI to 1 month), only in patients with high thrombotic risk.<sup>13</sup> In the absence of direct evidence, the duration of dual therapy should follow post-PCI recommendations, but should again be as short as possible (1–6 months) based on the bleeding risk. When TAVI is performed early post-PCI, it is unknown whether antithrombotic therapy should be continued peri-TAVI, but expert opinion advises continuing when PCI has been performed within 3 months because the risk for stent thrombosis is highest within this timeframe.

## Transcatheter aortic valve implantation valve thrombosis

Transcatheter aortic valve implantation valve thrombosis rarely leads to heart failure due to increased transvalvular gradients (1–3%).<sup>3–5</sup> In recent CT studies, subclinical leaflet thrombosis was identified in up to a quarter of patients on antiplatelet therapy, and there is evidence that (N)OAC effectively prevents and reverses leaflet thrombosis.<sup>14,15</sup> However, subclinical leaflet thrombosis may also regress spontaneously without changing antithrombotic therapy. Some observational studies showed an increase in thromboembolic events in patients with subclinical leaflet thrombosis, but this was not confirmed in the GALILEO and other studies. The PARTNER-3-CT sub-study only showed a slightly higher valvular gradient when subclinical leaflet thrombosis was present, both at 1 and 12 months. These CT series are, however, too small to conclude a detrimental impact of leaflet thrombosis on valve function or clinical outcome and there is no evidence to support routine CT for detection of subclinical leaflet thrombosis post-TAVI.

## Consensus statements for optimal antithrombotic therapy peri- and post-transcatheter aortic valve implantation

The choice of antithrombotic therapy should be based on both TAVI procedure and patients' characteristics, comorbidities, and/or co-medications that predispose to bleeding and thrombosis. Below we provide consensus statements for optimal antithrombotic therapy based on the latest evidence (*Graphical Abstract*).

### Pre-transcatheter aortic valve implantation

- Assessment of bleeding risk is mandatory.

- In patients without OAC indication, low-dose aspirin should be started pre-TAVI.
- In case of contraindication for aspirin, clopidogrel should be used.

### Peri-transcatheter aortic valve implantation

- Vitamin K anticoagulation or NOAC continuation or interruption should be decided on an individual basis.
- When VKA is continued, the international normalized ratio should be at the inferior limit of the therapeutic range (~2).
- Additional aspirin is not needed in OAC-treated patients.
- Unfractionated heparin with ACT of 250–300 s is preferred.
- (ACT-guided) reversal of UFH with protamine sulphate is reasonable.
- Bivalirudin is an alternative if UFH is contraindicated.
- Use of embolic protection devices is reasonable in patients at high risk of stroke.

### Post-transcatheter aortic valve implantation

- Periodical re-assessment of the bleeding risk is mandatory.
- Low-dose aspirin is preferred in the absence of OAC indication.
- Vitamin K anticoagulation or NOAC alone is preferred when there is an indication for OAC.
- After coronary stenting, if the bleeding risk is high, DAPT should be shortened to 1–3 months in case of CCS and to 3–6 months in case of ACS.
- After coronary stenting in patients on OAC, if the bleeding risk is high, clopidogrel should be shortened to 1–3 months in case of CCS and to 3–6 months in case of ACS.
- When coronary stenting is performed within 3 months pre-TAVI, continuing the indicated DAPT or OAC plus clopidogrel peri-TAVI should be considered.

## Supplementary material

Supplementary material is available at *European Heart Journal* online.

**Conflicts of interest:** J.t.B. reports lecture or consultancy fees from AstraZeneca, Eli Lilly, Daiichi Sankyo, The Medicines Company, AccuMetrics, Boehringer Ingelheim, Bristol-Myers Squibb, Pfizer, Bayer, Ferrer, and Idorsia. He received institutional research grants from ZonMw and AstraZeneca. He is the principal investigator of the POPular TAVI trial. D.S. reports lecture or consultancy fees from Bayer, Sanofi Aventis, Pfizer, Astra Zeneca, and Haemonetics S.A. B.R. reports speaker fee from Novartis, Bayer AG, and Medscape. E.v.B., M.G., J.G., P.L., L.T., and G.V. report no conflict of interest. B.C. reports consultancy fees from Biotronik, Colibri, Medtronic, Terumo and is minor shareholder of CERC. J.P.C. received institutional research grants from Bristol-Myers Squibb, Fédération Française de Cardiologie, Lead-Up, Medtronic, and WebMD. D.D. reports lecture or consultancy fees from Abbott, Medtronic, Boston Scientific, and Edwards Lifescience. D.G. reports institutional research grants from Bayer and BMS, and lecture fees from AstraZeneca and Bayer. E.L.G. reports lecture or consultancy fees from AstraZeneca, Bayer, Boehringer Ingelheim, Bristol-Myers Squibb, Pfizer, Lundbeck

Pharma, MSD, MundiPharma, Portola Pharmaceuticals, and Roche, and unrestricted research grants from Boehringer Ingelheim. A.S.P. reports consultant for Medtronic, ABBOTT, and Boston, receiving research fees from Boston, GADA, and ABBOTT. A.R. reports lecture or consultancy fees from Daiichi Sankyo, Bayer, Boehringer Ingelheim, Pfizer, and Bristol-Myers Squibb. A.W. reports lecture fees from Abbott, Boston Scientific, Edwards, and Medtronic. He is a proctor for Edwards and Medtronic. J.M. received an institutional research grant from Boston Scientific and lecture fees from Bristol-Myers Squibb, Edwards, Medtronic, and Astra Zeneca.

## References

- Baumgartner H, Falk V, Bax JJ, De Bonis M, Hamm C, Holm PJ, Jung B, Lancellotti P, Lansac E, Rodriguez Muñoz D, Rosenhek R, Sjögren J, Tornos Mas P, Vahanian A, Walther T, Wendler O, Windecker S, Zamorano JL, ESC Scientific Document Group. 2017 ESC/EACTS Guidelines for the management of valvular heart disease. *Eur Heart J* 2017;**38**:2739–2791.
- Otto CM, Nishimura RA, Bonow RO, Carabello BA, Erwin JP, Gentile F, Jneid H, Krieger EV, Mack M, McLeod C, O’Gara PT, Rigolin VH, Sundt TM, Thompson A, Toly C. 2020 ACC/AHA Guideline for the management of patients with valvular heart disease: a report of the American College of Cardiology/American Heart Association Joint Committee on Clinical Practice Guidelines. *Circulation* 2021;**143**:e72–e227.
- Dangas GD, Tijssen JGP, Wöhrle J, Søndergaard L, Gilard M, Möllmann H, Makkar RR, Herrmann HC, Giustino G, Baldus S, De Backer O, Guimarães AHC, Gullestad L, Kini A, von Lewinski D, Mack M, Moreno R, Schäfer U, Seeger J, Tchétché D, Thomitzek K, Valgimigli M, Vranckx P, Welsh RC, Wildgoose P, Volkl AA, Zazula A, van Amsterdam RGM, Mehran R, Windecker S, GALILEO Investigators. A controlled trial of rivaroxaban after transcatheter aortic-valve replacement. *N Engl J Med* 2020;**382**:120–129.
- Nijenhuis VJ, Brouwer J, Delewi R, Hermanides RS, Holvoet W, Dubois CLF, Frambach P, de Bruyne B, van Houwelingen GK, van der Heyden JAS, Toušek P, van der Kley F, Buyschaert I, Schotborgh CE, Ferdinande B, van der Harst P, Roosen J, Peper J, Thielen FWF, Veenstra L, Chan DRPP, Yin P, Swaans MJ, Rensing BJWM, van’t Hof AWJ, Timmers L, Kelder JC, Stella PR, Baan J, Ten Berg JM. Anticoagulation with or without clopidogrel after transcatheter aortic-valve implantation. *N Engl J Med* 2020;**382**:1696–1707.
- Brouwer J, Nijenhuis VJ, Delewi R, Hermanides RS, Holvoet W, Dubois CLF, Frambach P, De Bruyne B, van Houwelingen GK, Van Der Heyden JAS, Toušek P, van der Kley F, Buyschaert I, Schotborgh CE, Ferdinande B, van der Harst P, Roosen J, Peper J, Thielen FWF, Veenstra L, Chan Pin Yin DRPP, Swaans MJ, Rensing BJWM, van’t Hof AWJ, Timmers L, Kelder JC, Stella PR, Baan J, ten Berg JM. Aspirin with or without clopidogrel after transcatheter aortic-valve implantation. *N Engl J Med* 2020;**383**:1447–1457.
- Nijenhuis VJ, ten Berg JM, Hengstenberg C, Lefèvre T, Windecker S, Hildick-Smith D, Kupatt C, Van Belle E, Tron C, Hink HU, Colombo A, Claessen B, Sartori S, Chandrasekhar J, Mehran R, Anthopoulos P, Deliargyris EN, Dangas G. Usefulness of clopidogrel loading in patients who underwent transcatheter aortic valve implantation (from the BRAVO-3 randomized trial). *Am J Cardiol* 2019;**123**:1494–1500.
- Brinkert M, Mangner N, Moriyama N, Keller LS, Hagemeyer D, Crusius L, Lehnick D, Kobza R, Abdel-Wahab M, Laine M, Stortecy S, Pilgrim T, Nietlispach F, Ruschitzka F, Thiele H, Linke A, Toggweiler S. Safety and efficacy of transcatheter aortic valve replacement with continuation of vitamin K antagonists or direct oral anticoagulants. *JACC Cardiovasc Interv* 2021;**14**:135–144.
- Rodés-Cabau J, Masson JB, Welsh RC, García Del Blanco B, Pelletier M, Webb JG, Al-Qoofi F, Généreux P, Maluenda G, Thoenes M, Paradis JM, Chamandi C, Serra V, Dumont E, Côté M. Aspirin versus aspirin plus clopidogrel as antithrombotic treatment following transcatheter aortic valve replacement with a balloon-expandable valve: the ARTE (Aspirin Versus Aspirin + Clopidogrel Following Transcatheter Aortic Valve Implantation) randomized clinical trial. *JACC Cardiovasc Interv* 2017;**10**:1357–1365.
- Hindricks G, Potpara T, Dagres N, Arbelo E, Bax JJ, Blomström-Lundqvist C, Boriani G, Castellà M, Dan GA, Dilaveris PE, Fauchier L, Filippatos G, Kalman JM, La MM, Lane DA, Lebeau JP, Lettino M, Lip GYH, Pinto FJ, Thomas GN, Valgimigli M, Van Gelder IC, Van Putte BP, Watkins CL. 2020 ESC Guidelines for the diagnosis and management of atrial fibrillation developed in collaboration with the European Association for Cardio-Thoracic Surgery (EACTS). *Eur Heart J* 2021;**42**:375–498.
- Butt JH, De Backer O, Olesen JB, Gerds TA, Havers-Borgersen E, Gislason GH, Torp-Pedersen C, Søndergaard L, Køber L, Fosbøl EL. Vitamin K antagonists vs. direct oral anticoagulants after transcatheter aortic valve implantation in atrial fibrillation. *Eur Heart J Cardiovasc Pharmacother* 2021;**7**:11–19.
- Jochheim D, Barbanti M, Capretti G, Stefanini GG, Hapfelmeier A, Zadrozny M, Baquet M, Fischer J, Theiss H, Todaro D, Chieffo A, Presbitero P, Colombo A, Massberg S, Tamburino C, Mehilli J. Oral anticoagulant type and outcomes after transcatheter aortic valve replacement. *JACC Cardiovasc Interv* 2019;**12**:1566–1576.
- Abdul-Jawad Altisent O, Durand E, Muñoz-García AJ, Nombela-Franco L, Cheema A, Kefer J, Gutierrez E, Benítez LM, Amat-Santos JJ, Serra V, Eltchaninoff H, Alhasser SM, Elízaga J, Dager A, García Del Blanco B, Ortas-Nadal MDR, Marsal JR, Campelo-Parada F, Regueiro A, Del Trigo M, Dumont E, Puri R, Rodés-Cabau J. Warfarin and antiplatelet therapy versus warfarin alone for treating patients with atrial fibrillation undergoing transcatheter aortic valve replacement. *JACC Cardiovasc Interv* 2016;**9**:1706–1717.
- Valgimigli M, Bueno H, Byrne RA, Collet JP, Costa F, Jørgensen A, Juni P, Kastrati A, Kolh P, Mauri L, Montalescot G, Neumann FJ, Petricevic M, Roffi M, Steg PG, Windecker S, Zamorano JL, Levine GN, ESC Scientific Document Group. ESC Committee for Practice Guidelines (CPG), ESC National Cardiac Societies. 2017 ESC focused update on dual antiplatelet therapy in coronary artery disease developed in collaboration with EACTS: the Task Force for dual antiplatelet therapy in coronary artery disease of the European Society of Cardiology (ESC) and of the European Association for Cardio-Thoracic Surgery (EACTS). *Eur Heart J* 2018;**39**:213–260.
- De Backer O, Dangas GD, Jilaihawi H, Leipsic JA, Terkelsen CJ, Makkar R, Kini AS, Veien KT, Abdel-Wahab M, Kim WK, Balan P, Van Mieghem N, Mathiassen ON, Jeger RV, Arnold M, Mehran R, Guimarães AHC, Nørgaard BL, Kofoed KF, Blanke P, Windecker S, Søndergaard L, GALILEO-4D Investigators. Reduced leaflet motion after transcatheter aortic-valve replacement. *N Engl J Med* 2020;**382**:130–139.
- Makkar RR, Blanke P, Leipsic J, Thourani V, Chakravarty T, Brown D, Trento A, Guyton R, Babaliaros V, Williams M, Jilaihawi H, Kodali S, George I, Lu M, McCabe JM, Friedman J, Smalling R, Wong SC, Yazdani S, Bhatt DL, Bax J, Kapadia S, Herrmann HC, Mack M, Leon MB. Subclinical leaflet thrombosis in transcatheter and surgical bioprosthetic valves: PARTNER 3 cardiac computed tomography substudy. *J Am Coll Cardiol* 2020;**75**:3003–3015.